

Pulse corticosteroids for the management of extensive CNS tuberculosis presenting with acute-onset quadriparesis

Umang Arora¹, Prerna Garg¹, Shrawan Kumar Raut¹, Deepti Vibha², Upendra Baitha¹, Atin Kumar³, Pankaj Jorwal¹, Manish Soneja^{1,*}, Ashutosh Biswas¹

¹ Department of Medicine, All India Institute of Medical Sciences, Delhi, India;

² Department of Neurology, All India Institute of Medical Sciences, Delhi, India;

³ Department of Radiodiagnosis, All India Institute of Medical Sciences, Delhi, India.

SUMMARY Myelopathy in central nervous system tuberculosis is notorious for poor outcomes, determined by the severity of inflammation and cord level involved. Acute-onset quadriplegia or paraplegia in these cases represents a neuro-emergency. We report a young female with disseminated tuberculosis who presented with acute onset flaccid quadriparesis with loss of bladder and bowel function. Imaging helped identify the extensive involvement of the neuraxis. We propose that, in addition to anti-tubercular therapy, high-dose corticosteroids such as pulse methylprednisolone may result in a meaningful improvement and show greater rapidity of response in cases of severe central nervous system inflammation such as arachnoiditis or myelopathy.

Keywords Tuberculosis, meningitis, myelopathy, immunosuppression

To the Editor,

Central nervous system (CNS) tuberculosis is a severe form of extrapulmonary tuberculosis with mortality rates of 30-40%, and up to 60% with advanced disease at presentation (1). Clinical manifestations include fever, headache, vomiting, seizures, and altered sensorium. Acute-onset quadriparesis is an unusual presentation due to spinal cord involvement (2). Rapid onset of disease indicates an acute insult which may be reversed by aggressive treatment, reducing the severity of long term sequelae. We present a case wherein early administration of supraphysiologic doses of steroid ('pulse') therapy led to early sustained recovery.

A 14-year-old girl was symptomatic with low-grade fever, weight-loss and anorexia for one-year, abdominal distension for two months, and persistent headache for one month. She had been clinically diagnosed earlier as disseminated tuberculosis based on peritoneal thickening and moderate ascites on ultrasound of the abdomen, patchy consolidation in both lung fields, and close contact with a known case of pulmonary tuberculosis (father). She had been non-adherent to the prescribed anti-tubercular therapy (ATT), interrupting treatment twice for several weeks at a time due to frequent vomiting.

She presented to us in the emergency department with weakness of all four limbs, loss of sensation below the umbilicus, and urinary retention for one day. On

examination, she had intact sensorium and normal cranial nerves. The visual acuity was found reduced to 6 ft/60 ft in both eyes, and fundus examination was normal. Motor testing revealed decreased power in both upper limbs (3/5, modified Medical Research Council (mMRC) grading) and no movements in the lower limbs (0/5) or trunk. Deep tendon reflexes in bilateral ankle, knee, and triceps were absent while bilateral biceps and supinator were weak (1+). Both plantars were mute. Sensory testing revealed a loss of vibration, touch, and pain below the level of the umbilicus, spontaneous paraesthesias in upper limbs, and normal facial sensation. Bowel and bladder function were lost.

Within 24 hours of presentation, power declined in upper limbs to 0/5 (mMRC). In the setting of disseminated tuberculosis, we suspected spinal cord involvement. The symmetric involvement, acute onset, and absence of bony deformity, girdle sensation and root pain was suggestive of non-compressive myelopathy (tuberculous transverse myelitis, anterior spinal cord infarction) instead of compressive myelopathy (spine tuberculosis, tuberculomas, epidural abscess). Blood investigations revealed normocytic anemia (hemoglobin 9 gm/dL), leukocytosis (12,000/ μ L, 75% neutrophils, 9% lymphocytes and 10% monocytes), and elevated erythrocyte sedimentation rate (56 mm/hour). Platelet count, renal and liver functions were normal, and antibodies against human immunodeficiency virus (HIV)

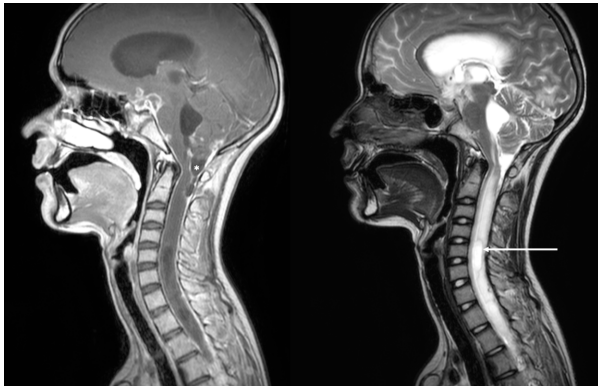


Figure 1. Magnetic resonance imaging (MRI) of the brain and spine demonstrates several manifestations of CNS tuberculosis. Post-contrast T1 weighted (T1w, left panel) and T2w(right panel) sagittal MRI shows diffuse leptomeningeal enhancement and thickening over the brainstem and spinal cord, exudates at the suprasellar cistern, base of the fourth ventricle, and the cervico-medullary junction leading to focal CSF loculation posterior to it (marked with an asterisk). Significant oedema and syrinx extending throughout the cord are evident, most prominent at C5-C6 level (white arrow).

were absent. Lumbar puncture was attempted twice by different experienced operators, but both attempts failed. The cause of quadripareisis was evident on neuroimaging: florid arachnoiditis, cord oedema, and syringomyelia were prominent (Figure 1), along with hydrocephalus (Figure 2).

She was started on ATT (rifampicin, isoniazid, pyrazinamide, and levofloxacin) and intravenous steroids (pulse methylprednisone (500 mg for five days) followed by dexamethasone). Power in both upper limbs improved gradually and symmetrically in a proximal to distal manner to 3/5 (mMRC) by day 3, and to 4+/5 (mMRC) by day 7 of pulse corticosteroids. A ventriculoperitoneal shunt was subsequently inserted. There was no incidence of dyselectrolytemia, hypertension, hyperglycemia, fluid overload, or hospital-acquired infection during her admission. She was prescribed high dose dexamethasone (0.4mg/kg) for one month after discharge. At two months of follow-up, she had regained functionality in upper limbs but remained paraplegic.

In over two-third cases, quadripareisis or paraparesis in tuberculosis results from compressive myelopathy due to tubercular spondylitis (2). Less often, it is attributable to the direct involvement of spinal cord or nerve roots by the arachnoiditis, resulting in tuberculous myelopathy (3). This can present with either an upper or lower motor neuron pattern of weakness, is frequently associated with the development of a syrinx and bears poor prognosis (4). It has reportedly been confused with Guillain-Barré syndrome when presenting as only flaccid weakness without bladder or sensory involvement (5). Binocular or monocular visual impairment frequently occurs in tuberculous meningitis. It is usually a consequence of the basal meningeal exudates encasing the optic nerve or chiasma resulting in retrobulbar optic neuritis, with possible contribution from raised intracranial pressure,

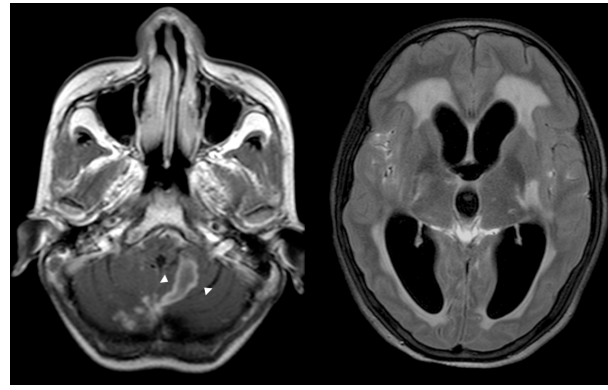


Figure 2. MRI Brain T1w post-contrast (left panel) and T2-FLAIR (right panel) shows ring and disc enhancing lesions in the cerebellar vermis measuring 2.8 cm (white arrowhead), and severe hydrocephalus with periventricular oozes.

vasculitic infarcts, and use of certain anti-tubercular drugs (ethambutol, fluoroquinolones, and linezolid) (6). The absence of papillitis or papilledema on fundoscopy in the setting of extensive basal exudates is consistent with retrobulbar neuritis as the cause of vision loss in our patient.

The treatment of CNS tuberculosis targets the mycobacterium, the inflammatory response, and prevention of complications such as hydrocephalus (e.g., ventricular drainage) or ischemic stroke (e.g., aspirin) (7). ATT usually combines four drugs of which rifampicin, isoniazid, and pyrazinamide are well accepted, while ethambutol is often the fourth agent. Fluoroquinolones (levofloxacin, moxifloxacin), aminoglycosides (streptomycin, amikacin) and linezolid have been studied as alternatives to ethambutol owing to its poor CNS penetration, and are non-inferior in terms of mortality (7).

Corticosteroids are remarkable adjuncts to ATT in CNS tuberculosis, particularly in meningitis where short-term mortality is reduced by 25% (8). Prevention of hydrocephalus, vasculitic infarction and IRIS (immune reconstitution syndrome) probably underly the mortality benefit, although without significant improvement in neurological sequelae in survivors (9). The standard doses of dexamethasone for meningitis described by Thwaites *et al.* have often been empirically applied to the other manifestations of CNS tuberculosis (1). However, the specific steroid used, its dose, route of administration, and the rate of taper have been a topic of intense discussion. In children with tubercular meningitis, small randomized studies have found no mortality difference between high and low dose steroids (4 mg/kg vs. 2 mg/kg prednisone) (10). These doses were equivalent to 0.75 mg/kg dexamethasone, thus not comparable to contemporary practice. A retrospective analysis reported an early switch from intravenous to oral route of dexamethasone in patients with tuberculomas or basal exudates and better neurological status at baseline but did not evaluate the outcomes with this approach (11).

The present case explored the role of pulse steroid therapy in CNS tuberculosis prompted by the abrupt clinical presentation and radiological findings of severe inflammation. Pulse therapy implies the intermittent administration of suprapharmacologic doses of steroids to enhance the therapeutic effect and reduce the side effects, defined arbitrarily as 250 mg prednisone or equivalent per day (12). Although methylprednisone is the typical steroid employed in pulse therapy, dexamethasone is longer acting (biological t_{1/2} 36-72 hours vs. 12-36 hours), more potent, cheaper and does not cause significant fluid retention (12). A comparative study of intravenous dexamethasone and pulse methylprednisolone in tubercular meningitis found a similar reduction in death and visual impairment between the groups (13). Pulse steroids have also been tried for tuberculous arachnoiditis and cerebral vasculitis (5,14). However, none of these reports describe the time to clinical improvement. The improvement in upper limb power from 0 to 3/5 (mMRC) within three days of pulse steroids indicates an improvement in nervous tissue function at the cervical cord level. Of the multiple pathologies that plagued the cervical cord in our patient, cord oedema would possibly respond the earliest. At the same time, syringomyelia and arachnoiditis involve significant structural damage and may take longer to respond to therapy. Clinical recovery in the present cases was faster than we had expected based on our previous experience managing such cases at our tertiary center. We propose that pulse therapy, with either methylprednisolone or dexamethasone, may be worth exploring to induce a faster clinical response for the torment of CNS tuberculosis.

Funding: None.

Conflict of Interest: The authors have no conflicts of interest to disclose.

Consent: Informed consent has been obtained from the patient's guardian (mother).

References

- Thwaites GE, Nguyen DB, Nguyen HD, *et al.* Dexamethasone for the treatment of tuberculous meningitis in adolescents and adults. *N Engl J Med.* 2004; 351:1741-1751.
- Vaishnav B, Suthar N, Shaikh S, Tambile R. Clinical study of spinal tuberculosis presenting with neuro-deficits in Western India. *Indian J Tuberc.* 2019; 66:81-86.
- Hristea A, Constantinescu RVM, Exergian F, Arama V, Besleaga M, Tanasescu R. Paraplegia due to non-osseous spinal tuberculosis: report of three cases and review of the literature. *Int J Infect Dis.* 2008; 12:425-429.
- Gupta R, Garg RK, Jain A, Malhotra HS, Verma R, Sharma PK. Spinal cord and spinal nerve root involvement (myeloradiculopathy) in tuberculous meningitis: *Medicine (Baltimore).* 2015; 94:e404.
- Singanamalla B, Saini AG, Sidana V, Saini L, Sankhyan N, Singh P. Progressive quadriplegia and inflammation: A common disease, a rare presentation. *Indian J Tuberc.* 2020; 67:336-339.
- Garg RK, Malhotra HS, Kumar N, Uniyal R. Vision loss in tuberculous meningitis. *J Neurol Sci.* 2017; 375:27-34.
- Davis A, Meintjes G, Wilkinson RJ. Treatment of tuberculous meningitis and its complications in adults. *Curr Treat Options Neurol.* 2018; 20:5.
- Prasad K, Singh MB, Ryan H. Corticosteroids for managing tuberculous meningitis. *Cochrane Database Syst Rev.* 2016; 4:CD002244.
- Thwaites GE, Macmullen-Price J, Chau TTH, Mai PP, Dung NT, Simmons CP, White NJ, Hien TT, Summers D, Farrar JJ. Serial MRI to determine the effect of dexamethasone on the cerebral pathology of tuberculous meningitis: an observational study. *Lancet Neurol.* 2007; 6:230-236.
- Shah I, Meshram L. High dose versus low dose steroids in children with tuberculous meningitis. *J Clin Neurosci.* 2014; 21:761-764.
- Paliwal VK, Das A, Anand S, Mishra P. Intravenous steroid days and predictors of early oral steroid administration in tuberculous meningitis: A retrospective study. *Am J Trop Med Hyg.* 2019; 101:1083-1086.
- Sinha A, Bagga A. Pulse steroid therapy. *Indian J Pediatr.* 2008; 75:1057-1066.
- Malhotra HS, Garg RK, Singh MK, Agarwal A, Verma R. Corticosteroids (dexamethasone versus intravenous methylprednisolone) in patients with tuberculous meningitis. *Ann Trop Med Parasitol.* 2009; 103:625-634.
- Javard N, Certal Rda S, Stirnemann J, Morin AS, Chamouard JM, Augier A, Bouchaud O, Carpentier A, Dhote R, Dumas JL, Fantin B, Fain O. Tuberculous cerebral vasculitis: Retrospective study of 10 cases. *Eur J Intern Med.* 2011; 22:e99-104.

Received February 9, 2021; Revised March 12, 2022; Accepted March 18, 2022.

**Address correspondence to:*

Manish Soneja, Department of Medicine, 3rd floor, Teaching Block, All India Institute of Medical Sciences, Ansari Nagar, Delhi, India, 110029.
Email: manishsoneja@gmail.com

Released online in J-STAGE as advance publication March 24, 2022.