

Angiosarcoma of the thoracic wall responded well to nanoparticle albumin-bound paclitaxel: A case report

Naofumi Hara¹, Nobukazu Fujimoto^{2*}, Yosuke Miyamoto¹, Tomoko Yamagishi¹, Michiko Asano¹, Yasuko Fuchimoto¹, Sae Wada¹, Shinji Ozaki¹, Hideyuki Nishi³, Takumi Kishimoto⁴

¹Department of Respiratory Medicine, Okayama Rosai Hospital, Okayama, Japan;

²Department of Medical Oncology, Okayama Rosai Hospital, Okayama, Japan;

³Department of Surgery, Okayama Rosai Hospital, Okayama, Japan;

⁴Department of Internal Medicine, Okayama Rosai Hospital, Okayama, Japan.

Summary An 81-year-old woman visited a local clinic due to chest pain and a skin induration on the right precordia. She had a history of right breast cancer, and she had undergone a mastectomy and radiation therapy 10 years prior. Computed tomography (CT) imaging of the chest demonstrated a lobular mass that involved the right anterior thoracic wall and partially extruded from the thoracic cavity into the subcutaneous tissue. The tumor was surgically excised, and pathological analyses yielded a diagnosis of angiosarcoma. Five months after the operation, CT imaging showed multiple masses on the right pleura, indicating a local relapse and pleural dissemination of the angiosarcoma. Systemic chemotherapy composed of nanoparticle albumin-bound paclitaxel (nab-PTX) (80 mg/m²) was delivered weekly. After 4 courses of chemotherapy, the tumors regressed remarkably. Nab-PTX may be an effective treatment option for recurrent or metastatic angiosarcoma.

Keywords: Angiosarcoma, paclitaxel, chemotherapy

1. Introduction

Angiosarcoma is an extremely rare malignant vessel tumor that comprises 1% of all soft tissue sarcomas (1). It develops in subcutaneous tissue at many sites in the body, and a previous medical history of trauma, breast cancer, and/or radiotherapy are considered risk factors for the disease. Localized tumors are treated with surgical removal. However, for recurrent and unresectable conditions, there is limited evidence to support chemotherapy regimens. Here, we describe a patient with angiosarcoma that developed in the thoracic wall, which responded well to systemic chemotherapy composed of nanoparticle albumin-bound paclitaxel (nab-PTX).

2. Case report

An 81-year-old woman was referred to our hospital for an examination due to right chest pain. She had a history of right breast cancer and had undergone a mastectomy and adjuvant radiotherapy 10 years prior. Upon examination, a skin induration with tenderness was found on the right precordia. Computed tomography (CT) imaging of the chest demonstrated right pleural effusion and a lobular mass that involved the right anterior thoracic wall; this mass had partially extruded from the thoracic cavity into the subcutaneous tissue (Figure 1A). On enhanced CT images, the mass showed a contrast effect in the early stages of the arterial phase. The tumor was surgically excised. Pathological analyses of the tumor showed disarranged growth of hyperchromatic and vasoformative mesenchymal tumor cells with abnormal mitosis (Figure 2A). Immunohistochemical analyses revealed that the cells were positive for CD31 (Figure 2B) and CD34 (Figure 2C), but negative for epithelial markers, S-100 (Figure 2D) and D2-40 (Figure 2E). Based on these findings, the diagnosis was confirmed as angiosarcoma. Five months after the operation, CT images showed

Released online in J-STAGE as advance publication February 15, 2016.

*Address correspondence to:

Dr. Nobukazu Fujimoto, Department of Medical Oncology, Okayama Rosai Hospital, 1-10-25 Chikkomidorimachi, Okayama 702-8055, Japan.

E-mail: nobufujimot@gmail.com

multiple masses on the right pleura, indicating a local relapse and pleural dissemination of the angiosarcoma (Figure 1B). Systemic chemotherapy composed of nab-PTX (80 mg/m²) was delivered weekly. After 4 courses of chemotherapy, the masses in the pleura regressed remarkably (Figure 1C). The only adverse event was alopecia, no myelosuppression or neurotoxicity was observed. After a total of 14 courses of chemotherapy, multiple tumors reappeared, and the patient died at

18 months after the initial diagnosis. Autopsy was not allowed.

3. Discussion

Angiosarcoma is an uncommon malignant vessel tumor. Angiosarcoma can develop in the subcutaneous tissue in almost all parts of the body, but the most common sites are the head and neck, followed by the breast and liver (2). Angiosarcoma of the pleura is extremely rare (3). A history of breast cancer and radiation therapy are known risk factors for this disease (4,5), and both these factors were present in the current case study. There is limited evidence to support chemotherapy regimens for unresectable and recurrent angiosarcomas; however, a few reports have suggested that anthracyclines, ifosfamide, and taxanes are potential treatment options. A retrospective study showed that, when paclitaxel was used to treat unresectable angiosarcomas, progression-free survival was achieved for 6.8 months for scalp angiosarcoma and 2.8 months for sites below the clavicle (6). Nab-PTX is a novel, soluble, polyoxyethylated, castor oil-free, biologically interactive form of paclitaxel, which allows shorter infusion times and requires no premedication for hypersensitive reactions. Nab-PTX has been approved for breast cancer (7), non-small cell lung cancer (8), and gastric cancer (9) in Japan. Moreover, in the future, it will be used in more patients as an alternative to PTX. In the current case, nab-PTX was delivered to an aged patient with recurrent angiosarcoma that had disseminated in the pleura. This

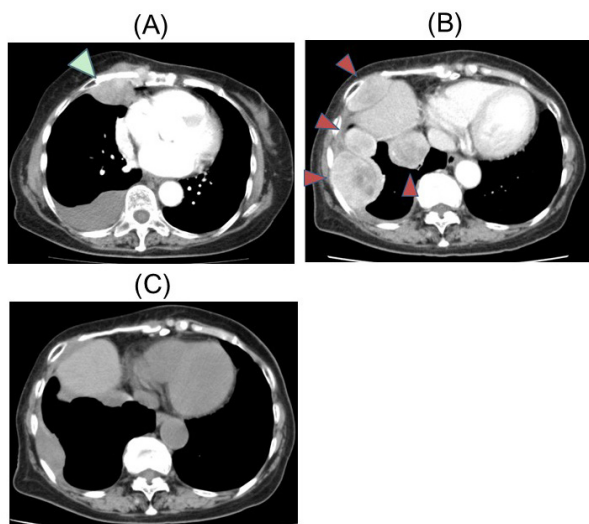


Figure 1. Computed tomography images of the chest. (A) Right pleural effusion and a lobular mass (white arrowhead) were observed at the initial examination. (B) Multiple masses on the right pleura (red arrowheads) appeared 5 months after the operation. (C) Regressed masses on the pleura after 4 courses of chemotherapy.

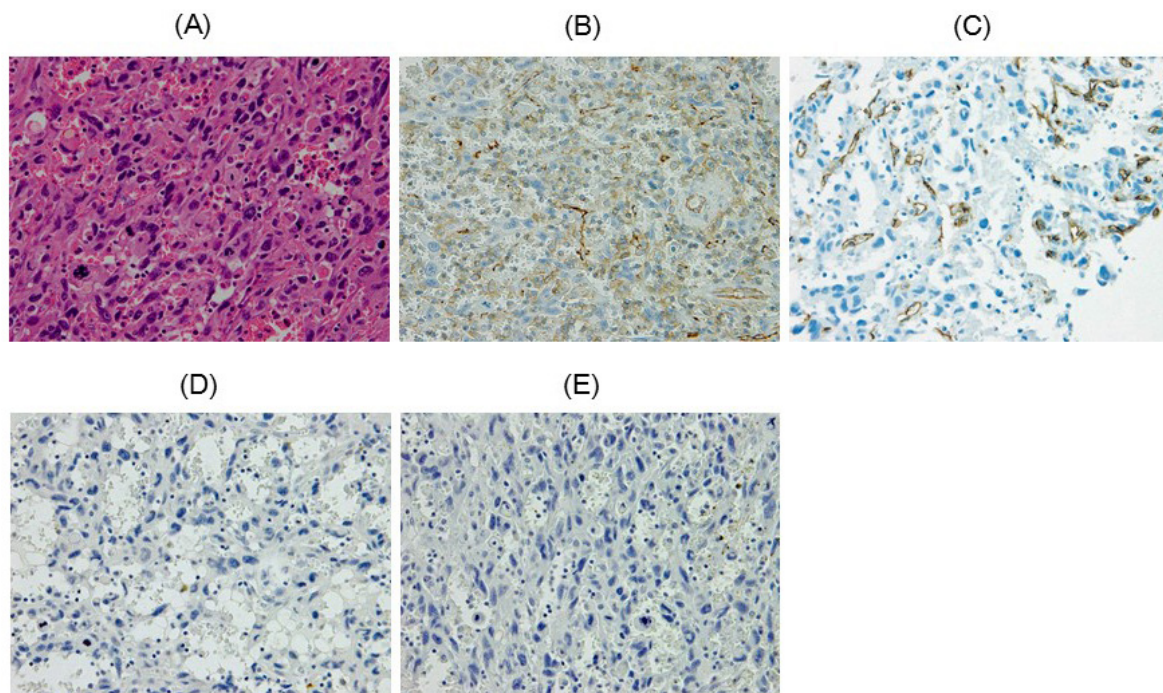


Figure 2. Pathological analyses. (A) Resected tumor specimen showed disarrayed growth of hyperchromatic and vasoformative mesenchymal tumor cells with abnormal mitosis (×40). Immunohistochemical analyses revealed that the cells were positive for CD31 (B) and CD34 (C), but negative for epithelial markers, S-100 (D) and D2-40 (E) (×40).

treatment elicited a favorable response and few adverse events, though the tumor acquired resistance eventually. To our knowledge, the current case was the first to show that angiosarcoma significantly responded to nab-PTX. Our results suggested that weekly administration of nab-PTX may be an effective treatment option for recurrent angiosarcoma.

In conclusion, we described a case of angiosarcoma in the pleura, which showed a significant response to nab-PTX.

Acknowledgements

Supported by "The research, development, and dissemination of projects related to nine fields of occupational injuries and illnesses" of the Japan Labour Health and Welfare Organization and by grants-in-aid from the Ministry of Health, Labor and Welfare, Japan.

References

1. Wanebo HJ, Kones R, MacFarlane JK, Eilber FR, Byers RM, Elias EG, Spiro RH. Head and neck sarcoma: report of the Head and Neck Sarcoma Registry. Society of Head and Neck Surgeons Committee on Research. *Head Neck*. 1992; 14:1-7.
2. Albores-Saavedra J, Schwartz AM, Henson DE, Kostun L, Hart A, Angeles-Albores D, Chable-Montero F. Cutaneous angiosarcoma. Analysis of 434 cases from the Surveillance, Epidemiology, and End Results Program, 1973-2007. *Ann Diagn Pathol*. 2011; 15:93-97.
3. Zhang S, Zheng Y, Liu W, Yu X. Primary epithelioid angiosarcoma of the pleura: a case report and review of literature. *Int J Clin Exp Pathol*. 2015; 8:2153-2158.
4. Karlsson P, Holmberg E, Johansson KA, Kindblom LG, Carstensen J, Wallgren A. Soft tissue sarcoma after treatment for breast cancer. *Radiother Oncol*. 1996; 38:25-31.
5. Blanchard DK, Reynolds C, Grant CS, Farley DR, Donohue JH. Radiation-induced breast sarcoma. *Am J Surg*. 2002; 184:356-358.
6. Fury MG, Antonescu CR, Van Zee KJ, Brennan MF, Maki RG. A 14-year retrospective review of angiosarcoma: clinical characteristics, prognostic factors, and treatment outcomes with surgery and chemotherapy. *Cancer J*. 2005; 11:241-247.
7. Gradishar WJ, Tjulandin S, Davidson N, Shaw H, Desai N, Bhar P, Hawkins M, O'Shaughnessy J. Phase III trial of nanoparticle albumin-bound paclitaxel compared with polyethylated castor oil-based paclitaxel in women with breast cancer. *J Clin Oncol*. 2005; 23:7794-7803.
8. Rizvi NA, Riely GJ, Azzoli CG, Miller VA, Ng KK, Fiore J, Chia G, Brower M, Heelan R, Hawkins MJ, Kris MG. Phase I/II trial of weekly intravenous 130-nm albumin-bound paclitaxel as initial chemotherapy in patients with stage IV non-small-cell lung cancer. *J Clin Oncol*. 2008; 26:639-643.
9. Koizumi W, Morita S, Sakata Y. A randomized Phase III trial of weekly or 3-weekly doses of nab-paclitaxel versus weekly doses of Cremophor-based paclitaxel in patients with previously treated advanced gastric cancer (ABSOLUTE Trial). *Jpn J Clin Oncol*. 2015; 45:303-306.

(Received January 5, 2016; Revised February 8, 2016; Accepted February 9, 2016)