

Early small bowel perforation due to aflibercept

Toufic Moussallem, Chetana Lim, Michael Osseis, Francesco Esposito, Eylon Lahat, Liliana Fuentes, Chady Salloum, Daniel Azoulay*

Department of Hepato-Biliary and Pancreatic Surgery and Liver Transplantation, AP-HP Henri Mondor Hospital, Créteil, France.

Summary

In patients with malignancy who receive aflibercept based chemotherapy, gastrointestinal perforation is among the reported adverse events with a prevalence of 1.9%. This complication may lead to mortality up to 10.8%. We here report a case of small bowel perforation that occurred fifteen days after the first cycle of aflibercept in a 58-year old female who had metachronous colorectal liver metastases. Emergency laparotomy was performed and revealed a small bowel perforation without any anastomotic dehiscence. Surgery was followed by uneventful outcome. The use of aflibercept in patients with malignancy may be associated with very early gastrointestinal perforation and this should be known by oncologist and surgeons.

Keywords: Aflibercept, chemotherapy, gastrointestinal, perforation, angiogenesis inhibitor

1. Introduction

Spontaneous gastrointestinal perforation is a well-known and potentially life-threatening adverse event associated with Bevacizumab-based chemotherapy (1). Aflibercept, a new angiogenesis inhibitor targeting the vascular endothelial growth factor (VEGF) pathway, is currently used in combination with FOLFIRI in metastatic colorectal cancer patients progressing following an oxaliplatin-based chemotherapy since 2012 (2). As expected, Aflibercept may be also associated with increased risk of gastrointestinal perforation. The incidence of gastrointestinal perforation associated with Aflibercept has been estimated to be 1.9% with an associated mortality of 10.8% (3). We report here a case of small bowel perforation that occurred early in a patient receiving aflibercept for the treatment of metachronous colorectal liver metastases.

2. Case Report

Eight months after right colectomy and pancreaticoduodenectomy for a PT4N0M0 right colon adenocarcinoma, a 58-year old female developed metachronous liver metastasis. There was no evidence of tumor recurrence in all small intestine segments or peritoneal carcinomatosis. Neoadjuvant chemotherapy included FOLFIRI in combination with Aflibercept. Fifteen days after the first cycle of FOLFIRI/aflibercept combination, the patient complained for acute abdominal pain with nausea. The patient did not report any corticosteroid or nonsteroidal anti-inflammatory drug use. In physical examination, there were no signs of abdominal hernia. Computed tomography showed a pneumoperitoneum due to small bowel perforation. There were no signs of small intestine volvulus or occlusion, or internal hernia. In addition, the preoperative imaging confirmed patency of the superior mesenteric artery and vein. Emergent laparotomy confirmed the spontaneous mid-gut perforation (Figure 1A). Primary direct suture of the perforation was performed. Because of the softness of the small bowel wall with a risk of tearing and subsequent risk of secondary perforation, an obliteration of the perforation was performed using the round ligament (Figure 1B). The round ligament was dissected, divided and the umbilical portion of the round ligament was sutured on the small bowel. The postoperative course was uneventful. Aflibercept was

Released online in J-STAGE as advance publication October 11, 2017.

*Address correspondence to:

Dr. Daniel Azoulay, Department of Hepato-Biliary and Pancreatic Surgery and Liver Transplantation, AP-HP Henri Mondor Hospital, 51 Avenue du Marechal de Lattre de Tassigny, 94010 Créteil, France.

E-mail: daniel.azoulay@aphp.fr

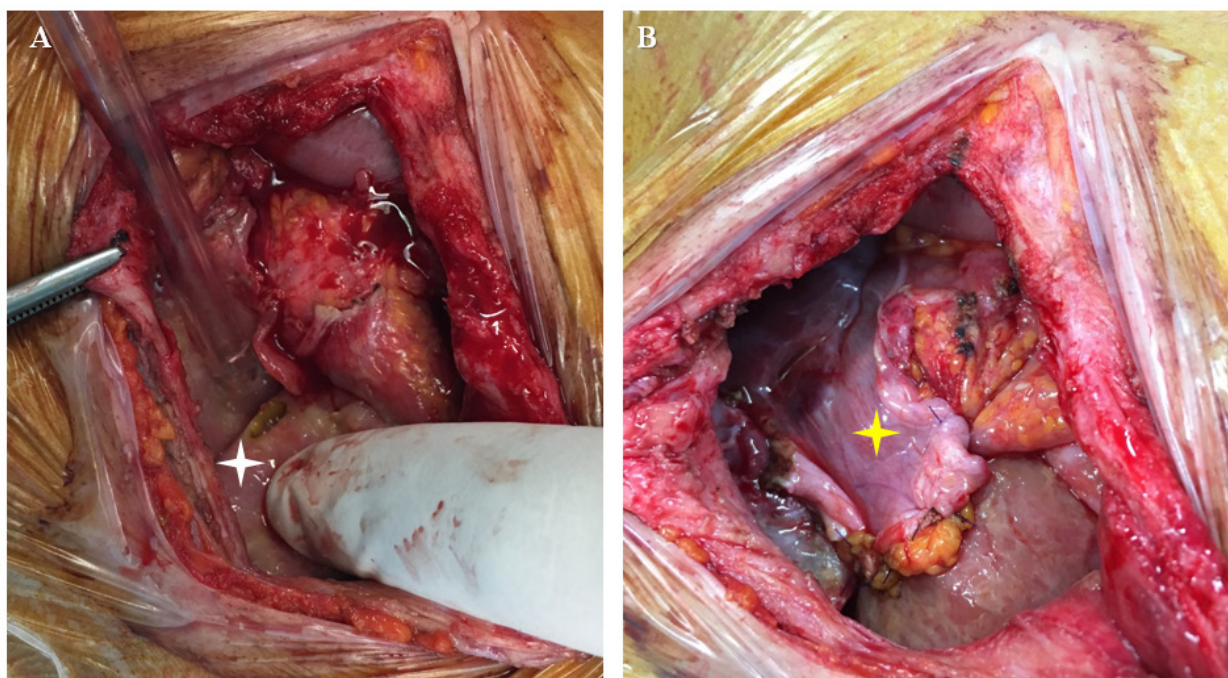


Figure 1. Intraoperative view of the small bowel perforation due to Aflibercept. A. Before obliteration by the round ligament (white star). **B.** After primary surgical suture and obliteration by the round ligament (yellow arrow).

discontinued postoperatively. The patient underwent liver resection 3 months later. She is doing well 3 months after hepatectomy with normal bowel function.

3. Discussion

Gastrointestinal perforation during or after treatment with Aflibercept was reported in patients with metastatic colorectal cancer (4,5). The present report has important clinical implications. First, in the present case, small bowel perforation occurred fifteen days after the first cycle of aflibercept. In the literature, time of occurrence of this complication has, to the best of our knowledge, never been described (4,5). Second, gastrointestinal perforation does not usually mean anastomotic dehiscence.

In the present case, the surgical treatment of the perforated small bowel consisted in performing simple surgical suture combined with the interposition of the round ligament. The use of the round ligament has been reported in the treatment of perforated peptic ulcer (6), but its use for obliteration of small bowel perforation has, to the best of our knowledge, never been reported.

In conclusion, the present report shows that the use of aflibercept in patients with malignancy may be associated with very early gastrointestinal perforation and this should be known by oncologist and surgeons.

References

1. Hapani S, Chu D, Wu S. Risk of gastrointestinal perforation in patients with cancer treated with bevacizumab: a meta-analysis. *Lancet Oncol.* 2009; 10:559-568.
2. FDA approves aflibercept (zaltrap) for metastatic colorectal cancer. *Oncology (Williston Park).* 2012; 26:842, 873.
3. Qi WX, Shen F, Qing Z, Xiao-Mao G. Risk of gastrointestinal perforation in cancer patients treated with aflibercept: a systematic review and meta-analysis. *Tumor Biol.* 2014; 35:10715-10722.
4. Van Cutsem E, Tabernero J, Lakomy R, Prenen H, Prausová J, Macarulla T, Ruff P, van Hazel GA, Moiseyenko V, Ferry D, McKendrick J, Polikoff J, Tellier A, Castan R, Allegra C. Addition of aflibercept to fluorouracil, leucovorin, and irinotecan improves survival in a phase III randomized trial in patients with metastatic colorectal cancer previously treated with an oxaliplatin-based regimen. *J Clin Oncol.* 2012; 30:3499-3506.
5. Tang PA, Cohen SJ, Kollmannsberger C, Bjarnason G, Virik K, MacKenzie MJ, Lourenco L, Wang L, Chen A, Moore MJ. Phase II clinical and pharmacokinetic study of aflibercept in patients with previously treated metastatic colorectal cancer. *Clin Cancer Res.* 2012; 18:6023-6031.
6. Costalat G, Dravet F, Alquier Y, Noel P, Vernhet J. Treatment of perforated peptic ulcer using the round ligament under coeloscopy. *J Chir (Paris).* 1991; 128:91-93.

(Received July 17, 2017; Revised September 18, 2017; Accepted September 22, 2017)